# Percutaneous Ethanol Injection of unresectable medium to large sized Hepatomas Using a Multi-pronged Needle: Efficacy and Safety

**C. S. Ho**[1], J. R. Kachura[1], S. Gallinger[2], D. Grant[2], P. Greig[2], I. McGilvray[2], J. Knox[3], M. Sherman[3], F. Wong[3], D. Wong[3]

Department of Medical Imaging[1], Surgery[2, &] Medicine [3], University of Toronto, University Health Network & Mt Sinai Hospital, Toronto, Canada

Corresponding author

C. S. Ho MB, BS, FRCPC

Department of Medical Imaging
Toronto General Hospital
585 University Avenue
NCSB 1C – 559
Toronto, Ontario, Canada
M5G 2N2

E-mail: cs.ho@uhn.on.ca

Phone: 416 340 4800 ext 2679/ 3371 Fax: 416 593 0502

**ABSTRACT**

**Purpose:** Fine needles with end-hole or multiple side holes have traditionally been used for percutaneous ethanol injection (PEI) of hepatomas. This study retrospectively evaluates the safety and efficacy of PEI of unresectable medium to large (3.5 – 9cm) hepatomas using a multi-pronged needle and with conscious sedation.

**Material/Methods:** Twelve patients, 8 men and 4 women (age 51 -77 years, mean: 69) received PEI for hepatomas, mostly subcapsular or exophytic in location with average tumor size of 5.6 cm (range: 3.5 cm – 9.0 cm). Patients were consciously sedated and an 18G retractable multi-pronged needle (Quadrafuse needle; Rex Medical, Philadelphia, PA) was used for injection under real time ultrasound guidance. By varying the length of the prongs and rotating the needle, the alcohol was widely distributed within the tumor. Progress of ablation was monitored by contrast-enhanced ultrasound, CT or MR after each weekly injection and within a month after the final (third) injection and 3 months thereafter.

**Results**: An average total of 63 ml (range 20 ml – 154 ml) of alcohol was injected per patient in an average of 2.3 sessions. Complete necrosis was noted in 8 patients, (67%), near complete necrosis (90% - 99%) in 2 (16.7%) and partial success (50% - 89%) in 2 (16.7%). Follow-up in the first 9 months showed local recurrence in 2 patients and new lesions in another. There was no mortality. One patient developed renal failure, liver failure and localized perforation of the stomach. He responded to medical treatment and surgery was not required for the perforation. One patient had severe post-procedural abdominal pain and fever, and another had transient hyperbilirubinemia; both recovered with conservative treatment.

**Conclusion**: PEI with a multi-pronged needle is a new, safe and efficacious method in treating medium to large sized HCC under conscious sedation. Its survival benefits require further investigations.

**Key Words**: Liver, Hepatocellular carcinoma, Percutaneous Ethanol Injection.

## INTRODUCTION

Two methods, the conventional and the one-shot or single-session method, have been described for percutaneous ethanol injection (PEI) for treatment of hepatomas. Both depend on real time ultrasound for guidance and either the end-hole Chiba needle or closed ended, multiple side-hole needle (PEIT needle; Hakko, Tokyo, Japan; Bernardino needle, Cook, Bloomington, IN) is used for alcohol injection(1, 2, 3). The conventional PEI is performed under conscious sedation for treatment of small hepatomas (< 5cm). With this method, a small amount (2 ml to 10 ml) of alcohol is injected at each session and multiple sessions (3 -12) are required to complete the treatment. The newer, single-session or one-shot PEI was introduced for large hepatomas (> 5 cm) but can also be used for small lesions. With this technique, a large volume of alcohol is injected under general anesthesia in one single session.

Both methods of PEI treatment have been shown to be safe and effective in treating hepatomas. In two retrospective, non-randomized studies, the conventional PEI has been shown to offer survival benefit matching that of surgical resection in treating small hepatomas (4,5). The results of one-session PEI, however, are conflicting. Some investigators reported (6) no difference in long-term survival between large and small hepatomas. However, others found it less effective for large than for small hepatocellular carcinoma (7) .

We have used a retractable, multiple-pronged needle (Quadrafuse needle; RexMedical, Philadelphia, PA) for PEI under conscious sedation to treat unresectable, medium (3-5 cm) and large sized (> 5cm) hepatomas. We call this multi-pronged PEI and present our initial results, aiming at evaluating its efficacy and safety. To our knowledge this method of PEI has not been previously reported.

## MATERIAL AND METHODS

This study was approved by Institutional Review Board. Selection for alcohol injection was based on consensus at weekly meetings of our multi-disciplined hepatoma board. Board members consisted of surgeons experienced in hepatobiliary surgery and/or liver transplant, hepatologists, interventional radiologists, medical and radiation oncologists. Medium (3 cm -4.9cm) to large (>5 cm) hepatomas, particularly those exophytic or subcapsular in location were selected for PEI using the multi-pronged needle. Indications for treatment included intent to cure, bridge to liver transplant and palliation. There were 12 patients, 8 men and 4 women (age 51 -77 years, mean: 69) each with at least one unresectable solitary hepatoma with size > 3 cm. The hepatomas were considered difficult for RF ablation, because of their large size or unfavorable locations. Cirrhosis was classified according to Child-Pugh classification. All patients except one were asymptomatic. The exception was a 77 year-old woman who had an emergency hospital admission because of sudden onset of severe abdominal pain. She was found to have a subcapular bleeding from rupture of a 9 cm hepatocellular carcinoma. Ablative treatment was aimed at preventing further bleeding.

Prior to the procedure, all patients had a consultation with the interventional radiologist during which the nature, benefits and risks of the procedure were explained. An ultrasound assessment was performed to determine if the lesion was accessible with ultrasound guidance and the best approach for PEI. Informed consents were signed and coagulation screening tests obtained prior to the procedure.

Patients were given intravenous Fentanyl citrate ( Sabex Inc, Boucherville, Quebec) and Midazolam hydrochloride (Versed; Sabex Inc, Boucherville, Quebec) for conscious sedation from the beginning of and during the procedure. Ultrasound was performed to locate the lesion and for selection of an optimal entry site. 1% Xylocaine was used for

local anesthesia. An 18G retractable multi-pronged needle (Quadrafuse; RexMedical, Philadelphia, PE) was used for injection. The needle (fig 1) has three retractable prongs, extendable to a maximum diameter of 5 cm. Under real- time ultrasound guidance, the needle was inserted to the target lesion, with its shaft placed in the middle and its tip at its far end. The prongs or tynes were then extended to an appropriate diameter such that their tips were positioned just within the perimeter of the tumor. Absolute alcohol was then injected and monitored by ultrasound. The alcohol created hyperechoic areas within the tumor and increased in size as more alcohol was injected. While injecting, the tynes of the needle were retracted gradually until they were complete. The needle was then rotated 60 degrees and the tynes re-extended once again to its former diameter. Alcohol was once again injected as before. In lesions larger than 5cm, the needle was withdrawn 1 cm to 2 cm proximally after completing injection at the far end and the tynes completely retracted. The tynes were then redeployed as described before and the injection process was repeated. At the end of injection, the needle was withdrawn slowly from the lesion, the liver parenchyma and finally, the body.

The total volume of alcohol injected to the lesion was guided by the formula:

$$\text{Volume} = 4/3\pi R^3, \text{ where R is the radius of the tumor.}$$

The maximum volume injected per session was arbitrarily limited to 60 ml to minimize alcohol toxicity to the patient, especially respiratory depression. Injection was stopped when the maximal volume was reached; or when intolerable abdominal pain occurred; or when alcohol was seen to diffuse largely into the vascular system and without creating the hyperechoic effect within the tumor.

After the procedure, the patient was observed and monitored for 4 hours in our Day Unit before discharge.

The patient returned one week after for assessment and further injection if necessary. Progress of ablation was monitored by contrast-enhanced (Iodixanol, Visipaque, GE Health, USA) triphasic CT of the liver using multi-slice CT. For patients with contraindications for CT contrast injection, contrast-enhanced ultrasound (contrast agent: Perflutren Lipid Microsphere, Definity; Bristol-Meyer-Squipp, USA) or MR (contrast agent:: gadopentetate dimeglumine ,Magnevist; Schering, Berlin, Germany) was performed instead. Residual tumors when present were targeted at subsequent injection. After the final injection, follow-up imaging was performed 2 weeks later and thereafter every 3 months.

RESULTS

Eleven patients had liver cirrhosis due to hepatitis B (n=6) or C (n=3) or chronic alcohol use (n=2); 4 patients had Child-Pugh A cirrhosis and 7 patients had Child-Pugh B. One patient .had primary sclerosing cholangitis. Two patients had more than one hepatoma but in each only the dominant one, 5 cm in size or more, was treated. The other ten had solitary hepatomas. The average tumor size was 5.6 cm (range: 3.5 cm – 9.0 cm). Two of the hepatomas were located centrally; six were subcapsular and four exophytic in location. Seven patients were treated with intent to cure, 3 as bridge to transplant and 2 for palliation. The total volume of alcohol injected per patient was 63ml (20-154 ml); the average volume injected per session was 27 ml (range: 5 – 60 ml), and the average number of injections sessions per patient was 2.3 (range: 1 – 3).

Outcome of alcohol injection was categorized into: complete (100%), near complete (90% - 99%) and partial (50% - 89%) necrosis based on the contrast-enhanced studies 2 weeks after completion of injection. These are summarized in Table 1 and illustrated in Fig 2 -4.

There was no mortality related to the procedure. One patient had a major complication 3 days after the injection and was admitted to the hospital for hepatic encephalopathy and renal failure. He was treated conservatively and recovered. On follow-up imaging with enhanced CT scan, he was found to have localized perforation of the stomach. He was asymptomatic and a surgical consultation was sought. No treatment was deemed necessary. Two patients with large tumors developed post ablation fever and abdominal pain and responded to oral analgesics.

At 9 months follow up; all patients except one were alive. One patient died 6 months after treatment while traveling abroad. He had a respiratory illness complicated by multiple organ failure. Two patients had recurrent tumors at the ablated site and a new intrahepatic hepatocellular carcinoma occurred distant to the ablation in another.

## DISCUSSION

Although conventional or single-session PEI technique has been successfully used for treating small (< 5 cm) hepatomas with 5-year survival of 42% to 59% (6, 8), many investigators have turned their attention to RF ablation as the evolving new technology. In two prospective, randomized studies comparing RF ablation and conventional PEI, the former was found to have better clinical outcome than conventional PEI in treating small hepatomas - longer survival and lower incidence of local recurrence. In one study involving 114 patients with hepatomas less than 5 cm (9), the one- and 2-year survival rates of RF ablation were 100% and 98% compared with 96% and 88% in the PEI group; local recurrence-free survival rates were 98%, 96% and 83%, 62% respectively. In another more recent study, 157 patients with hepatomas 4 cm or less were randomly assigned to 3 treatment groups: conventional PEI, higher-dose PEI or RF ablation (10). In this study, the corresponding rate of complete tumor necrosis was 88%, 92% and 96%. The tumor progression rate was lowest in the RF group; the overall survival rate and

cancer-free survival rate were both highest in the RF. In both studies, conventional PEI was used and an average of 6 sessions (ranging 2 -12) were required. The conclusions of these studies are not surprising, knowing how the alcohol was delivered to the lesions – in small aliquots at multiple sessions. The surprise is that the conventional PEI worked as well as it did. We think the outcome would be improved if a multi-pronged needle had been used. At the very least, the average number of injections would have been greatly reduced - our average number of injection was 2.3 for medium and large hepatomas.

RF ablation is less effective in treating large than small hepatomas as overlapping RF ablations are often required for large lesions. In saline-infused RF ablation, for instance, complete necrosis was achieved in 95% of small hepatomas less than 3 cm but this dropped to 71% for lesions 3 cm – 5 cm and only 12% for lesions larger than 5 cm (11). This was also true in another report using cooled-tip RF electrodes. In a study of 114 patients with hepatomas more than 3 cm (mean 5.4 cm), complete necrosis was attained in 47.6%, nearly complete necrosis in 31.7%, and partial necrosis in the remaining 20.6%.( 12). The same was true for liver metastases treated with RF ablation; 75% complete necrosis for lesions 3 cm or less and 11% for larger ones (13). Recently, Chen et al (14) reported a sophisticated mathematical treatment model for RF ablation and achieved a higher complete necrosis rate of 87% in 110 consecutive patients with tumors larger than 3.5 cm (mean 4.75 cm, range, 3.6– 7.0 cm); a one-year local recurrence rate of 19% for those with hepatocellular carcinomas. This treatment model however is complicated and the results may be difficult to duplicate.

Like RF ablation, the effectiveness of conventional PEI in treating HCC is also size-related, being more effective in small than in large hepatomas. For example, Vilana et al (15) has shown that conventional PEI achieved a complete response in all six patients with nodules less than 2 cm; 2 of the 7 with tumor size between 2 and 3 cm, and in only 1

of the 11 cases between 3 and 4 cm. When single session PEI was used, Giorgio et al reported no difference in long-term survival for small and large hepatomas (6). On the other hand, Meloni et al found that complete necrosis could be achieved in 58% of large encapsulated hepatomas; infiltrative, non-encapsulated lesions had poorer response (7). However, treatment of large hepatomas by PEI under conscious sedation has not been widely practised, as the conventional method would require many sessions of injections with uncertain success rate. This is both time consuming and labor intensive. Our results showed that the multi-pronged PEI has made it possible to treat medium and large hepatomas under conscious sedation in less than 3 injection sessions. This has radically changed our approach to local ablative therapy of hepatomas. We now use PEI for large hepatomas and RF for small lesions.

In our series, 67% of patients had complete necrosis and 16.7% near complete necrosis. This is comparable to those reported for one-shot PEI under general anesthesia (6,7) and RF treatment (12). With conscious sedation only, our patients required significantly fewer sessions of injections, 2.3 sessions on the average, than was recommended by Livraghi et al (16). They suggested the number of sessions to approximate twice the lesion diameter in centimeters. Had we followed this recommendation, an average of 11 sessions (average size of 5.6 x 2=11.2) would have been required instead. Our sessions of injection also compares favourably with those reported by Lin: average 6 sessions (2 -12) for treating hepatomas 4 cm or less (10).

The multi-pronged needle has several advantages over the Chiba or Bernardino needle used in alcohol injection. First, it allows more widespread distribution of alcohol within the tumor. When injected through a single needle, the alcohol is unevenly distributed within the lesion. Sequential PET scanning of the liver soon after injecting alcohol labeled with $^{11}C$ demonstrated this effect convincingly (17). This makes it difficult to

successfully ablate large hepatomas. By extending its tynes to the periphery of the lesion and rotating them later, the multi-pronged needle distributes the alcohol more evenly within the tumor. Second, as a result of more even distribution, alcohol is less likely to back track alongside the needle to the liver capsule as in a Chiba or Bernardino needle. This means less alcohol spill at the liver capsule/surface that may cause abdominal pain, sometimes so severe that injection has to be discontinued. Third, the multi-pronged needle requires a single puncture of the tumor as contrast to multiple punctures when using the Chiba needle for treating large hepatomas.

As noted earlier, conventional PEI has been shown to have a higher local recurrence rate than RF ablation in small hepatomas. This may again be related to the uneven alcohol distribution during and after injection, leaving behind clusters of viable tumor cells. We theorize that this deficiency may be corrected in part by the Quadrafuse needle by its ability to disperse alcohol quickly and at many different locations within the tumor. It is therefore conceivable the two major deficiencies of PEI: too many injections and high local recurrence may be addressed by using the multi-pronged needle. If this were substantiated in the long term, it may benefit many patients with large unresectable hepatomas who often have limited options for prolonging life.

One of our patients had significant complications including renal failure, hepatic encephalopathy and localized perforation of the stomach. He was admitted to hospital but recovered after conservative treatment. The perforation of the stomach was likely due to spilling of alcohol to the adjacent stomach. The spill may be due to one of the tynes being placed outside the tumor and in contact with the gastric serosa. Alternately, it may have been due to alcohol leakage along the needle during or after injection. Whatever the mechanism, it underscores the non-discriminatory, destructive effects of absolute alcohol, affecting normal and cancer cells alike. Despite this complication, we consider the

technique is safe as none of our patient required surgical remedy and the only patient with major complications recovered fully on conservative management.

We caution of high expectation extrapolated from our initial results. Despite our high rate of complete and near complete necrosis, we are uncertain if this would translate into long-term survival benefits. It has been shown that alcohol injection is less effective in treating infiltrative hepatomas than those well encapsulated. The use of multi-pronged needle is unlikely to change this. Large, well-circumscribed or encapsulated hepatomas on the whole have grown for a longer time than smaller ones. It is possible that undetectable, micro-metastases may already have occurred and negatively affects survival. Inserting the multi-pronged needle is more technically demanding than the conventional needle. Care should be taken to avoid placing any of its tynes outside the tumor confines to avoid alcohol spill. This can cause significant collateral damage as shown in our patient with localized gastric perforation. Despite the early promising results, we acknowledge that further validation is needed regarding its safety, effectiveness and long term benefits. This can only be derived from its application in a larger number of patients over a longer period of time

In summary, using the multi-pronged needle, medium and large hepatomas can be treated safely under conscious sedation in less than 3 sessions. We await more data and long-term results for further validation.

## Legend

Fig 1. Multi-pronged needle (Quadrafuse; RexMedical, Philadelphia, PA)

A. Photo showing the 18G needle with tynes retracted.

B. Photo showing the tynes fully extended

C. Photo showing set-up of the needle ready for injection. A three way stop-cock is attached to the hub of the input port so that a 20 ml syringe containing alcohol can be quickly delivered to the injecting syringe (10 ml) for injection.

. Fig 2. Complete necrosis (100%). 65-year old man with a 3.5 cm hepatocellular carcinoma in segment 6. A. Arterial phase of a triphasic CT scan showing arterial enhancement of the lesion. B. Arterial phase of repeat triphasic CT scan 2 weeks post alcohol injection showing complete necrosis of the lesion.

Fig 3. Near complete necrosis (90% - 99%). 56-year old man with 8 cm hepatocellular carcinoma in segment 8 of the liver. Triphasic CT scan showing the lesion in the arterial phase (A). Follow up CT after completion of alcohol injection. Minimal nodular contrast enhancement seen in the periphery of the lesion near the dome of the diaphragm (B). Complete ablation seen in the rest of the lesion (C)

Fig 4. Partial necrosis (50% - 89%). 77-year old woman with hepatocellular carcinoma was admitted for abdominal pain from subcapsular rupture of the tumor. She was treated for palliation to prevent further bleeding. A. Arterial phase of triphasic CT showed a large, 9 cm lesion in segment 7 with subcapsular hematoma. B. Triphasic CT, 2 weeks after alcohol injection showing moderate amount of residual tumor at the periphery of the lesion.

Table 1. Overall results of alcohol injection and according to hepatomas size

| | 3.5cm – 4.9cm<br>N=4 | 5 cm -7.9cm<br>N=6 | ≥ 8 cm<br>N=2 | Total<br>N=12 |
|---|---|---|---|---|
| Complete Necrosis (100%) | 3 (75%) | 4 (67%) | | 7 (58%) |
| Near complete necrosis (90% -99%) | 1 (25%) | 1 (16.6%) | 1 (50%) | 3 (25%) |
| Partial necrosis (50% -89%) | | 1 (16.6%) | 1 (50%) | 2 (17%) |

Fig 1A

Fig 1. Multi-pronged Quadrafuse needle ( RexMedical Philadelphia, PA).

A. Photo showing the 18G needle with tynes retracted.

Fig 1 B



Fig 1. Multi-pronged Quadrafuse needle ( RexMedical Philadelphia, PA).

B. Photo showing the tynes fully extended.

Fig 1C

Fig 1. Multi-pronged needle (Quadrafuse; RexMedical Philadelphia, PA).

C. Photo showing set-up of the needle ready for injection. A three-way stopcock is attached to the hub of the input port so that a 20 ml syringe containing alcohol can be quickly delivered to the injecting syringe (10 ml) for injection.

Fig 2A

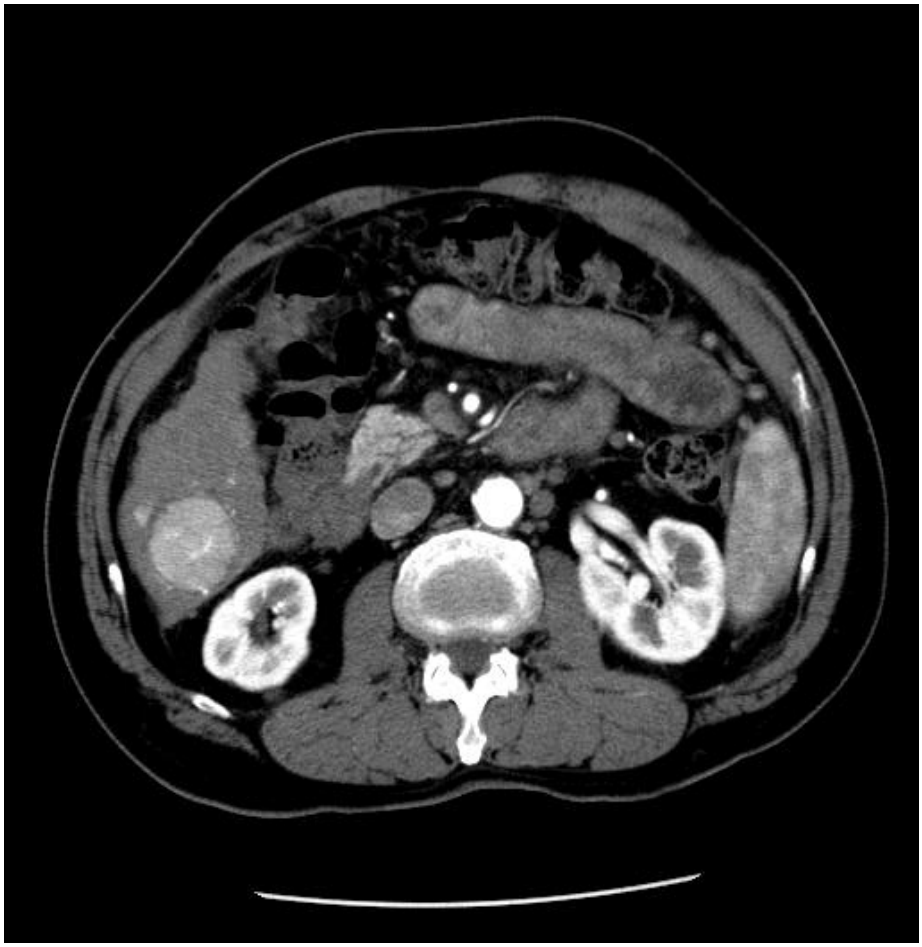

Fig 2. Complete necrosis (100%). 65-year old man with hepatocellular carcinoma in segment 6. A. Arterial phase of a triphasic CT scan showing arterial enhancement of the lesion. B. arterial phase of repeat triphasic CT scan 2 – weeks post alcohol injection showing complete necrosis of the lesion with no arterial enhancement during the arterial phase.

Fig 2B

Fig 2. Complete necrosis (100%). 65-year old man with hepatocellular carcinoma in segment 6. A. Arterial phase of a triphasic CT scan showing arterial enhancement of the lesion. B. arterial phase of repeat triphasic CT scan 2 – weeks post alcohol injection showing complete necrosis of the lesion with no arterial enhancement during the arterial phase.

Fig 3A

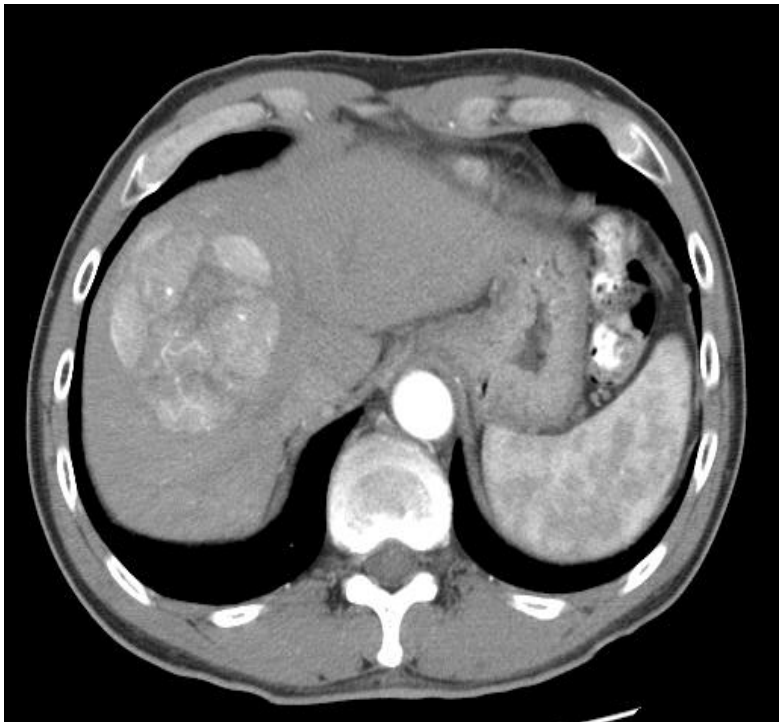

Fig 3. Near complete necrosis (90% - 99%). 56-year old man with 8 cm hepatocellular carcinoma in segment 8 of the liver. Triphasic CT scan showing the lesion in the arterial phase (A). Follow up CT after completion of alcohol injection. Arterial phase shows minimal marginal

enhancement in the periphery of the lesion near the dome of the diaphragm (B).

.Complete ablation seen in the rest of the lesion (C)

Fig 3B

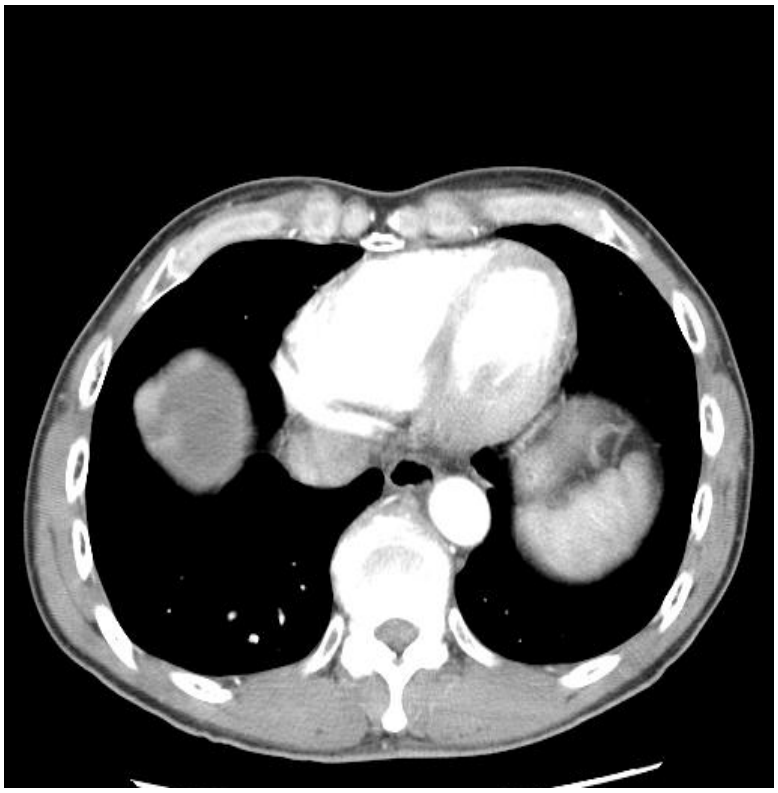

Fig 3. Near complete necrosis (90% - 99%). 56-year old man with 8 cm hepatocellular carcinoma in segment 8 of the liver. Triphasic CT scan showing the lesion in the arterial phase (A). Follow up CT after completion of alcohol injection. Arterial phase shows only marginal enhancement is seen in the periphery of the lesion near the dome of the diaphragm (B). .Complete ablation seen in the rest of the lesion (C)

Fig 3C

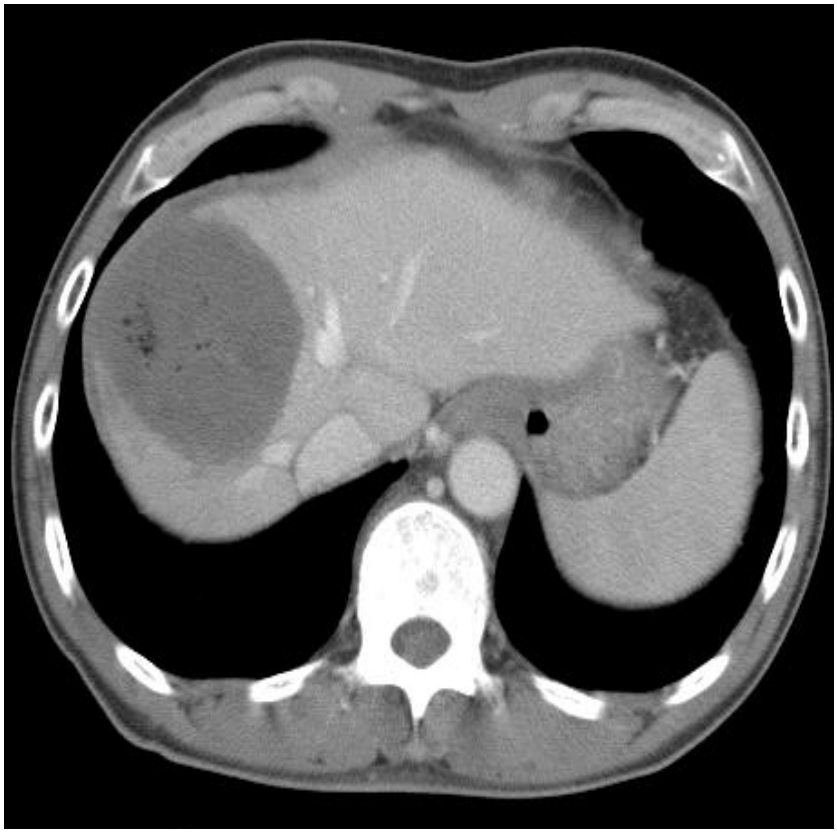

Fig 3. Near complete necrosis (90% - 99%). 56-year old man with 8 cm hepatocellular carcinoma in segment 8 of the liver. Triphasic CT scan showing the lesion in the arterial phase (A). Follow up CT after completion of alcohol injection. Arterial phase shows minimal marginal enhancement is seen in the periphery of the lesion near the dome of the diaphragm (B). Complete ablation seen in the rest of the lesion (C).

Fig 4A

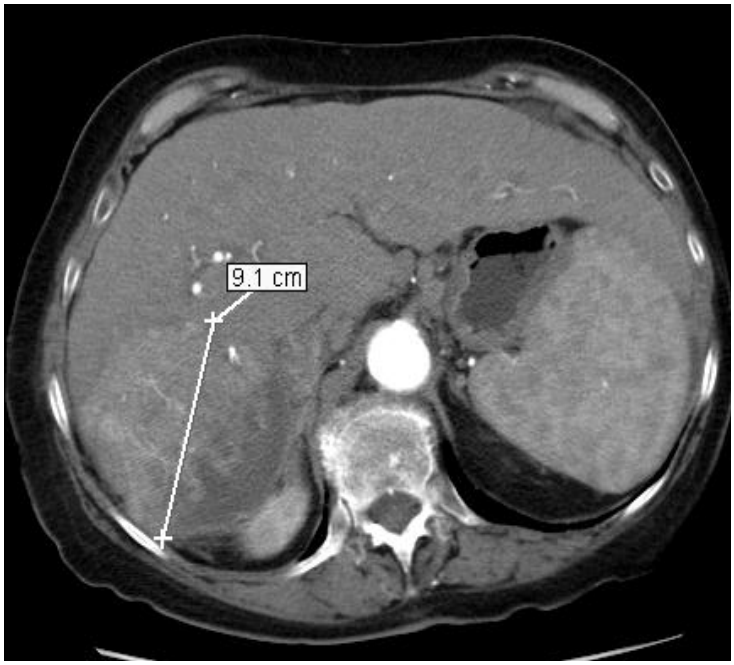


Fig 4B Fig 4. Partial necrosis (50% - 89%). 77-year old woman with hepatocellular carcinoma was admitted for abdominal pain from subcapsular rupture of the tumor. She was treated for palliation to prevent further bleeding. A. Arterial phase of triphasic CT showed a large, 9 cm lesion in segment 7 with subcapsular hematoma. B. Triphasic CT 2 weeks after alcohol injection showing moderate amount of residual tumor at the periphery of the lesion.

Fig 4B

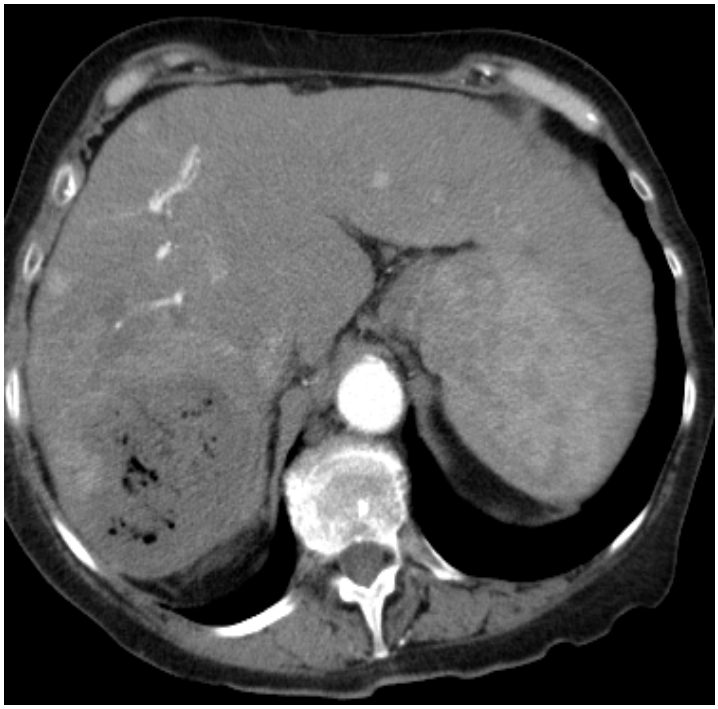

Fig 4. Partial necrosis (50% - 89%). 77-year old woman with hepatocellular carcinoma was admitted for abdominal pain from subcapsular rupture of the tumor. She was treated for palliation to prevent further bleeding. A. Arterial phase of triphasic CT showed a large, 9 cm lesion in segment 7 with subcapsular hematoma. B &C. Triphasic CT 2 weeks after alcohol injection showing moderate amount of residual tumor at the periphery of the lesion.

Fig 4C

Fig 4. Partial necrosis (50% - 89%). 77-year old woman with hepatocellular carcinoma was admitted for abdominal pain from subcapsular rupture of the tumor. She was treated for palliation to prevent further bleeding. A. Arterial phase of triphasic CT showed a large, 9 cm lesion in segment 7 with subcapsular hematoma. B & C. Triphasic CT 2 weeks after alcohol injection showing moderate amount of residual tumor at the periphery of the lesion.

## References


1. Livraghi, T; Festi, D; Monti, F; Salmi, A; Vettori, C. US-guided percutaneous alcohol injection of small hepatic and abdominal tumors. Radiology 1986; 161:309-312.
2. Livraghi,T, Vettori, C, Torzilli, G, Lazzaroni, S, Pellicano', S and Ravasi, S., Percutaneous ethanol injection of hepatic tumors: single session therapy under general anesthesia. AJR 1993; 161: 1065-1069.
3. Redvanly RD, Chezmar JL, Strauss RM, Galloway JR, Boyer TD, Bernardino ME. Malignant hepatic tumors: safety of high-dose percutaneous ethanol ablation therapy. Radiology. 1993; 188:283-5.
4. Livraghi T, Bolondi, L., Buscarini, L. et al. No treatment, resection and ethanol injection in hepatocellular carcinoma: a retrospective analysis of survival in 391 cirrhotic patients. J. Hepatol 1995; 22:522-526
5. Daniele B, De Sio I, Izzo F, Capuano G, Andreana A, Mazzanti R, et al. Hepatic resection and percutaneous ethanol injection as treatments of small hepatocellular carcinoma: a Cancer of the Liver Italian Program (CLIP 08) retrospective case-control study J Clin Gastroenterol. 2003;36:63-7
6. Giorgio A, Tarantino L, Stefano G, Perrotta A, Aloisio V, del theiscovo L, alaia A, Lettieri G V. Ultrasound-guided percutaneous ethanol injection under general anesthesia for treatment of hepatocellular carcinoma on cirrhosis: long-term results in 268 patients. Eur J Ultrasound. 2000;12:145-54.
7. Meloni F, Lazzaroni S, Livraghi T. Percutaneous ethanol injection: single session treatment. Eur J Ultrasound. 2001; 13:107-15

8. Livraghi T, Giorgio A, Marin G, Salmi A, de Sio I, Bolondi L, et al. Hepatocellular carcinoma and cirrhosis in 746 patients: long-term results of percutaneous ethanol injection. Radiology. 1995; 197:101-8

9. Lencioni RA, Allgaier HP, Cioni D, Olschewski M, Deibert P, Crocetti L, et al. Small hepatocellular carcinoma in cirrhosis: randomized comparison of radio-frequency thermal ablation versus percutaneous ethanol injection. Radiology. 2003;228:235-40

10. Lin SM, Lin CJ, Lin CC, Hsu CW, Chen YC. Radiofrequency ablation improves prognosis compared with ethanol injection for hepatocellular carcinoma < =4 cm. Gastroenterology. 2004; 127:1714-23.

11. Giorgio A, Tarantino L, de Stefano G, Scala V, Liorre G, Scarano F et al. Percutaneous sonographically guided saline-enhanced radio frequency ablation of hepatocellular carcinoma. AJR 2003;181:479-84

12. Livraghi T, Goldberg SN, Lazzaroni S, Meloni F, lerace T, Solbiati L, Gazelle GS. Hepatocellular carcinoma: radio-frequency ablation of medium and large lesions. Radiology. 2000;214:761-8.

13. Livraghi T, Goldberg SN, Monti F. et al. Saline enhanced radio-frequency tissue ablation in the treatment of liver metastases. Radiology 1997; 202:205-210.

14. Chen MH, Kun W, Yan K, Zou MW, Solbiati L, Liu *JB,* Dai Y. Large Liver Tumors: Protocol for Radiofrequency Ablation and Its Clinical Application in 110 Patients – Mathematic Model, Overlapping Mode, and Electrode Placement process. Raiology 2004;232:260-271

15. Livraghi T, Benedini V, Lazzaroni S, Meloni F, Torzilli G, Vettori C. Long term results of single session percutaneous ethanol injection in patients with large hepatocellular carcinoma. Cancer. 1998 l;83:48-57.

16. Livraghi T, Lazzaroni S, Meloni F, Torzilli G, Vettori C. Percutaneous ethanol injection. In: Livraghi T, Makuuchi M, Buscarini L, eds. Diagnosis and treatment of hepatocellular carcinoma. London, England: Greenwich Medical Media, 1997; 327-346.

17. Dimitrakopoulou-Strauss A, Strauss LG, Gutzler F, Irngartinger G, Kontaxakis G, Kim DK, et al. Pharmacokinetic Imaging of $^{11}C$ ethanol with PET in eight patients with hepatocellular carcinomas who were scheduled for treatemtn with percutaneous ethanol injection. Radiology 1999;211:681-686.